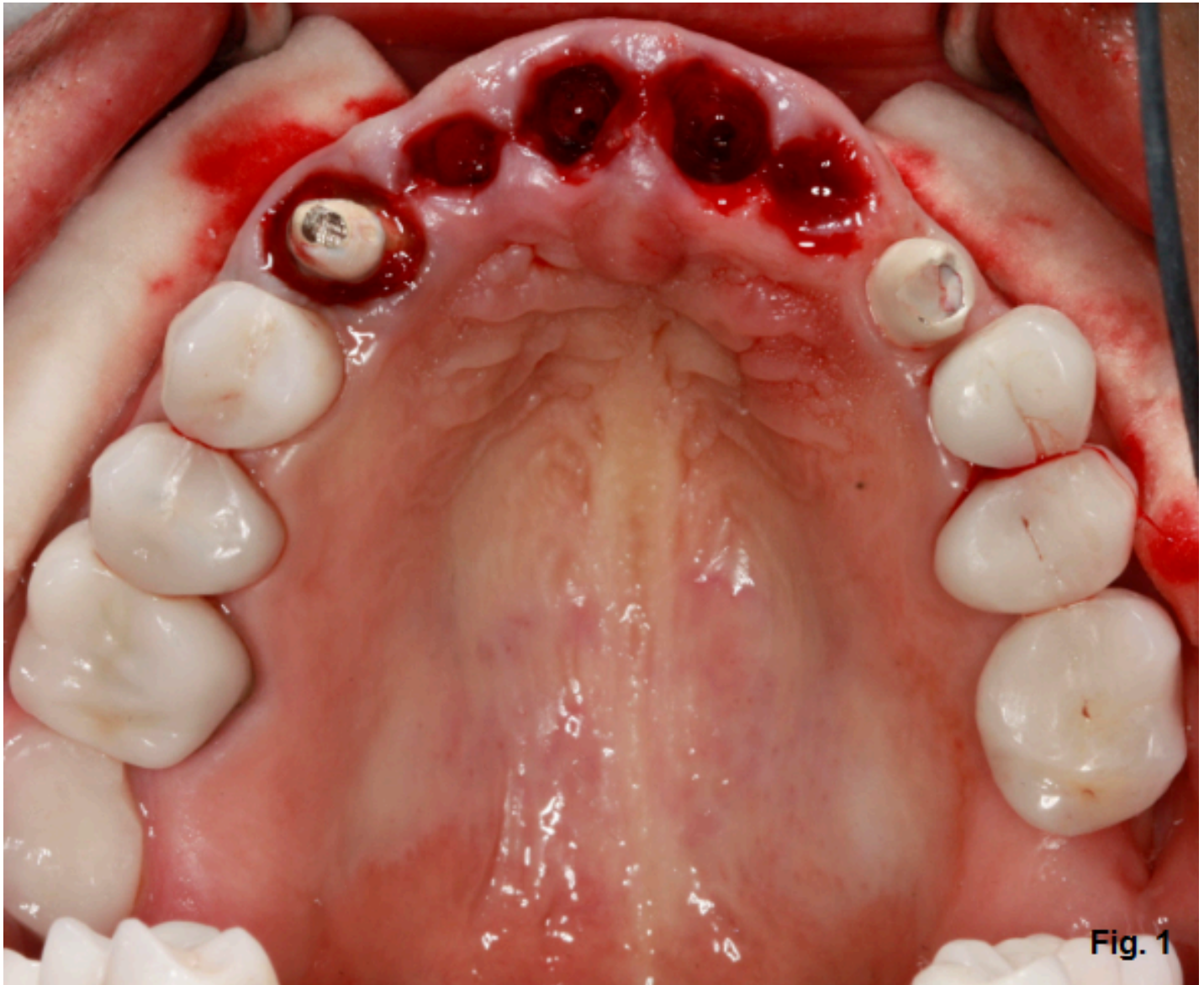


## IMPLANTS

[\(/spear-review/category/implants/\)](/spear-review/category/implants/)

# Removable Partial Denture for Maxillary Incisors

By Doug Bunting (</spear-review/author/doug-bunting/>) on June 11, 2018 | [\(/bookmarks/bookmark/34805\)](/bookmarks/bookmark/34805)[SHARE](#)**Fig. 1**

This patient has decided to have his upper maxillary incisors removed following a significant dental history that includes endodontic treatment, clinical crown lengthening, full coverage restorations and trauma. (Fig. 1)

[Live Chat](#)

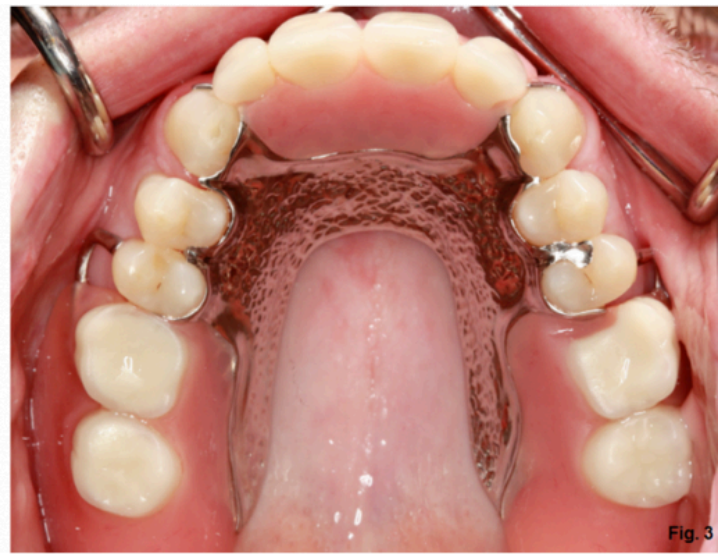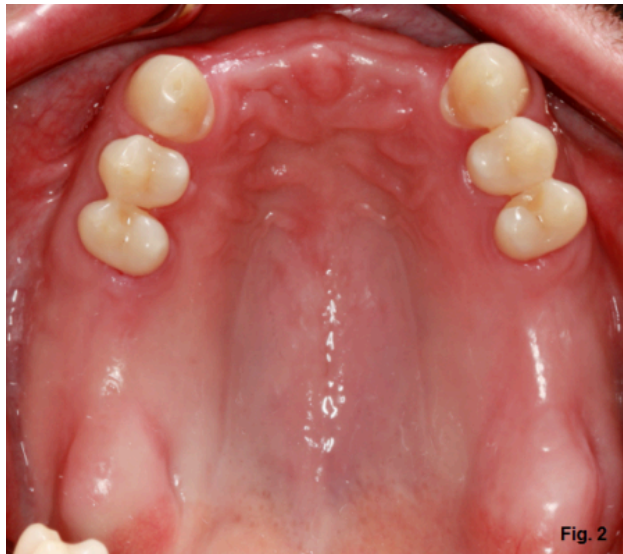Certainly, there are several restorative options available for treatment: tooth-supported fixed partial denture, dental implant (<https://www.speareducation.com/spear-review/category/implants/>)-supported fixed partial denture, individual dental implant-supported restorations, removable partial denture and of

course - no treatment. When there are several options available, it is really our responsibility to help the patient make the decisions on the options available based on their unique situation and circumstances.

Let's assume, for the sake of discussion, that the patient is interested in a removable partial denture for the anterior maxillary segment. What types of discussion items would be important for the patient to know prior to this point? What would you like to know based on what you see in the clinical photo?

Fresh extraction sites visible in the photos certainly lead to the question: Is this part of a phased approach to treatment where the removable partial will eventually be replaced? Will augmentation or grafting be indicated and how will that impact the provisional restoration? What type of provisional restoration would we like to have available? What about lip length and lip mobility, particularly as it pertains to gingival display?

The removable partial denture shown here has been in use for seven years with very little post-insertion maintenance other than six-month recall appointments. (Fig. 2)



While the clasp arms are minimal on the removable partial denture, they are still visible in the anterior segment in what represents a relatively low-cost and durable treatment option. (Fig. 3)

Restorative treatment options exist where clasps can be hidden or crowns with attachments can be made to help our patients with specific concerns related to partial dentures.

Back to the patient with the fresh extraction sites. Think about the design for a partial with a natural tooth for the right canine and a dental implant-supported restoration for the left canine. Any votes for a crown on the left canine? How about an attachment of some kind? Any special considerations related to a ball O-ring or Locator attachment?

*Douglas G. Benting* (<https://www.speareducation.com/spear-review/author/douglas-benting/>), DDS, MS, FACP, Spear Visiting Faculty and Contributing Author. [ [www.drBenting.com](http://www.drBenting.com) (<http://www.drBenting.com/>) ]

SPEAR SEMINARS



Save \$200 on Our Edentulous Seminar



ALT TEXT HERE

(<http://content.speareducation.com/treating-the-terminal-dentition-and-the-fully-edentulous-patient-20181027>)

Eager to master the essentials of treatment planning the terminal dentition and fully edentulous patient? The time is now - secure your limited-time voucher now to save \$200 on registration.